

Journal of Nephrology



Successful non-surgical management of bilateral emphysematous pyelonephritis despite adverse prognostic factors; report of a case and review of the literature

Seyed Reza Yahyazadeh¹, Tayebeh Soleymanian^{2*}

¹Nephrology and Urology Department, Shariati Hospital, Tehran University of Medical Sciences, Tehran, Iran

²Nephrology Department, Shariati Hospital, Tehran University of Medical Sciences, Tehran, Iran

ARTICLE INFO

Article type:
Case Report

Article history:
Received: 15 August 2018
Accepted: 6 November 2019
Published online: 24 November 2019

Keywords:
Emphysematous pyelonephritis
Acute renal failure
Type II diabetes
Hypertension

ABSTRACT

Emphysematous pyelonephritis (EPN) is a rare and ominous necrotizing kidney infection mainly involving diabetic patients. While prompt medical therapy with antibiotic and percutaneous catheter drainage is mainstay of management, nephrectomy should remain for unresponsiveness situations with poor prognostic factors. We introduced the clinical course of an old male presented with bilateral EPN which was successfully treated without nephrectomy regardless of various risk factors such as thrombocytopenia, impaired consciousness, and acute renal failure.

Implication for health policy/practice/research/medical education:

We treated a severe case of bilateral emphysematous pyelonephritis with circulatory/liver failure by intensive medical management including proper antibiotic therapy and percutaneous catheter drainage, rapid control of hyperglycemia, volume repletion, and treatment of renal failure complications with a full recovery and good outcome. Therefore, nephrectomy should be maintained for the failure of conservative management.

Please cite this paper as: Yahyazadeh SR, Soleymanian T. Successful non-surgical management of bilateral emphysematous pyelonephritis despite adverse prognostic factors; report of a case and review of the literature. J Nephrologypathol. 2020;9(3):e29. DOI: 10.34172/jnp.2020.29.

Introduction

Emphysematous pyelonephritis (EPN) is a life-threatening kidney and perinephric tissue infection, usually involving diabetic patients (1,2). Patients with EPN are typically septic with circulatory and liver failure (3). Ten percent of cases tend to be bilateral (3,4). Immediate treatment with antibiotic plus percutaneous catheter drainage/nephrectomy is highly recommended concerning high mortality of this ominous condition (5-7). With prompt diagnosis by CT scanning and robust antibiotic therapy along with catheter drainage, not only the need for urgent nephrectomy has been precluded or at least postponed but also the patients' survival has also been becoming more desirable (8,9).

Here we report a case of bilateral EPN with adverse

prognostic factors which successfully were handled by a non-surgical approach.

Case Presentation

A 70-year-old male with type II diabetes and hypertension for 7 years was presented to emergency department with complaints of fever, abdominal pain, nausea, vomiting, urinary symptoms and oliguria. His past-medical history was only positive for dental surgery 1.5 years before this admission. He claimed that his previous kidney function had been normal and he had no cardiovascular disease or diabetic retinopathy. Habitual history was negative. He was on glibenclamide, losartan, aspirin and atorvastatin.

On physical examination, he was ill, agitated and confused. His blood pressure was 98/65 mm Hg, with

*Corresponding author: Prof. Tayebeh Soleymanian,
Email: soleymanian@tums.ac.ir

respiratory rate of 26/min, pulse rate of 97/min, and oral temperature of 37.9°C. He was pale and icteric. Heart sounds were normal but scanty fine rales were heard on bases of the lungs. Bilateral costovertebral angle tenderness was detected. Abdominal examination appeared unremarkable. Peripheral pulses were symmetric but weak and distal lower extremities were cold. There was no neurologic problem or localizing manifestation. Initial laboratory work comprised complete blood count with leukocyte count of 14 200/ μ L and 88% neutrophils, hemoglobin of 11.5 g/dL (MCV; 90.7 fl, reticulocyte count; 1.5%), and platelet count of 82,000/ μ L, kidney function tests with blood urea nitrogen of 82.6 mg/dL and serum creatinine of 7.69 mg/dL; blood glucose of 576 mg/dL, ESR of 78 mm/h and CRP of 98 mg/l, blood chemistry of Na; 135 meq/L, K; 4.53 meq/L, HCO₃; 16.3 meq/L, calcium: 7.7 mg/dL, phosphorus; 8.3 mg/dL, magnesium; 2.2 mg/dL, uric acid; 8.7 mg/dL, serum albumin; 2.54 g/dL, AST; 42 IU/L, ALT; 32 IU/L, alkaline phosphatase; 514 IU/L, total bilirubin; 16 mg/dL, direct bilirubin; 9.1 mg/dL, PTT; 25.7 seconds, PT; 13.4 sec, and INR; 1.

Urinalysis revealed a specific gravity of 1010, protein; 3+, glucose; 2+, ketone; negative, RBC; many, WBC; many, bacteria; many, since no cast was seen. Viral markers were negative. D-Dimer and FDP were 1574 ng/mL (negative < 255) and > 20 mcg/mL (negative < 5), respectively. Electrocardiogram showed sinus tachycardia and there was mild congestion and pleural effusion on chest X-ray.

Report of abdominopelvic ultrasound was as follows: intrahepatic ducts were mildly prominent since common bile duct diameter was 10 mm. Gall bladder was edematous and its diameter was 95 × 30 mm filled with mild sludge. Bilateral enlarged edematous kidneys were detected. An abdominal computed tomography (CT) scan revealed diffusely enlarged kidneys with perinephric edema, extensive gas bubbles in left kidney (with extension

to cortex, pyelocalyceal system and left ureter) and in right kidney. Additionally, gas bubbles were noted in left retroperitoneal and left para psoas spaces, along with deep gluteal and left upper thigh soft tissues (Figure 1A).

A diagnosis of bilateral EPN with circulatory/renal/liver compromise caused by sepsis was made. Thus, supportive care with oxygen, intravenous fluids, insulin infusion, and empirical broad spectrum antibiotic therapy by meropenem and vancomycin was instituted. Because of confusion and oliguria with no response to IV fluid therapy, hemodialysis was commenced. On consultation with urologists, percutaneous catheter drainage for the left kidney was inserted (Figure 1B). Urine and blood culture were positive for *Escherichia coli* and sensitive to penems and amikacin, therefore, vancomycin was discontinued. Because of encouraging response to medical management, the need for surgery was not suggested.

The patient had a remarkable recovery over the next three to four weeks. Follow up CT-scan revealed incredible improvement with marked decrease of gas bubbles within the kidneys and para-nephric spaces, and decrease in kidneys' edema (Figure 1C). After 36 days of hospitalization, the patient was discharged while kidney function was being recovered and he became dialysis free (Table 1). He had no fever with negative urine and blood culture. One month after discharge, his serum creatinine was 1.7 mg/dL. After two years, he is healthy and his serum creatinine is 1.4 mg/dL with a good glycemic control on oral hypoglycemic agents.

Discussion

EPN is a necrotizing and gas-forming kidney infection which mainly involving diabetic middle and old ages of particularly women patients (10, 11). It is usually severe and life-threatening and has high mortality rate particularly in the absence of prompt appropriate antibiotic therapy and pertinent intervention (11, 12). The enteric gram-negative bacilli such as *Escherichia*

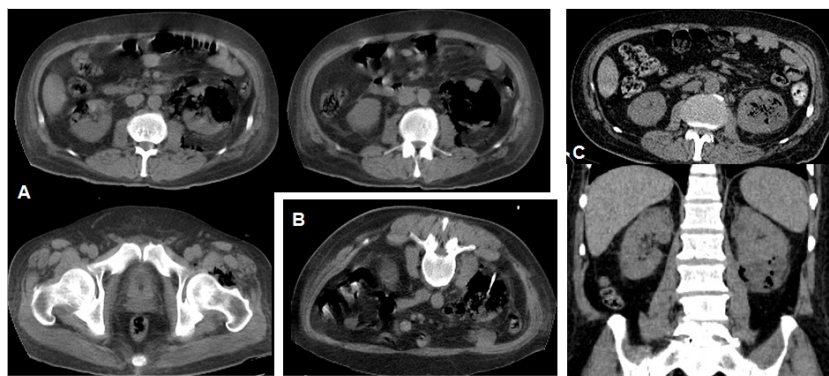


Figure 1. (A) CT scan of abdomen at admission revealing diffusely enlarged kidneys with perinephric edema, extensive gas bubbles in kidneys (most severe in left), and in left retroperitoneal, para psoas, deep gluteal and upper thigh soft tissues; (B) Percutaneous catheter drainage in left kidney on second day; (c) CT scan after 4 weeks revealing remarkable improvement of EPN.

Table 1. Laboratory data of the patient at different times of hospital stay

Laboratory data	Day 1	Day 3	Discharge
Glucose (mg/dL)	576	285	142
Creatinine (mg/dL)	7.69	6.58	3.8
HCO ₃ (meq/L)	16.3	18.1	22
Na (meq/L)	135	130	138
K (meq/L)	4.53	5.1	4.2
WBC/mm ³	14200	20020	8890
Hb (g/dL)	11.5	7.5	9.8
Platelets/mm ³	82000	55000	212000
Total bilirubin (mg/dL)	16	28.5	4.1
Direct bilirubin (mg/dL)	9.1	19.9	3.2
AST (U/L)	42	43	37
ALT (U/L)	32	36	15
Alkaline phosphatase (U/L)	514	531	316

coli (>60%), *Klebsiella pneumonia* (>20%), and *Proteus* account for most of the reported cases (13). Diabetes mellitus – which is involved in more than 80% of patients – and urinary tract obstruction are the major risk factors for EPN (13,14). Pathogenesis of EPN appears to be connected to growing of facultative anaerobic bacteria in a hypoxic and hyperglycemic tissue associated with a compromised immune response (13). Most patients are critically ill and presenting with fever, chills, nausea, vomiting, flank or abdominal pain, while circulatory/liver may compromise by sepsis. Acute renal failure requiring dialysis is a common complication of EPN in patients with bilateral infection or unilateral involvement in a single functioning kidney (12). Treatment of EPN has been evolving from an aggressive intervention of nephrectomy or open drainage to a more conservative approach with percutaneous catheter drainage of purulent substance and gas along with appropriate systemic antibiotic therapy (13,15,16). Mortality rate of conservative management has been reported to be half of the emergent nephrectomy (13% versus 25%) (16).

Classification of EPN based on CT-scan findings could help in appraising prognosis and proper treatment. Four classifications have been defined in which class I is associated with gas in the collecting system only; class II is linked to gas in the renal parenchyma without extension to the extra-renal space; class III is related to extension of gas or abscess to the perinephric space (class IIIA) or the pararenal space (class IIIB). Accordingly, in class IV, there is bilateral EPN or a solitary functioning kidney with EPN. Class III and IV have particularly been associated with adverse outcomes (13). Additionally, presence of renal parenchymal necrosis has been involved in a more

fulminant course and higher death (17). Patients with class III or IV EPN and two or more risk factors of renal impairment, thrombocytopenia, altered mental status, and shock have unfavorable outcome (13,18,19). Based on clinical data, patients with EPN should primarily be treated by proper parenteral antibiotic plus percutaneous catheter drainage, and in case of unresponsiveness to percutaneous catheter drainage, nephrectomy is indicated. Nephrectomy should be considered earlier in class III EPN patients with two or more risk factors. Bilateral drainage along with antibiotic therapy is recommended in patients with bilateral kidney involvement (class IV), while nephrectomy is the last resort to preserve renal function (13,14).

Conclusion

In summary, as reported by others, we treated a severe case of bilateral EPN with circulatory/liver failure by intensive medical management including proper antibiotic therapy and percutaneous catheter drainage, rapid control of hyperglycemia, volume repletion, and treatment of renal failure complications with a full recovery and good outcome. Therefore, nephrectomy should be maintained for the failure of conservative management.

Authors' contribution

SRY and TS handled the patient both. They contributed to the preparing and editing of the patient equally. All authors read and signed the final edition too.

Conflicts of interest

The authors declared no competing interests.

Ethical considerations

Ethical issues including plagiarism, double publication, and redundancy have been completely observed by the authors. The patient gave his consent to publish as a case report.

Funding/Support

The authors declared no funding or support from any institution.

References

- Ahlering TE, Boyd SD, Hamilton CL, Bragin SD, Chandrasoma PT, Lieskovsky G, et al. Emphysematous pyelonephritis: a 5-year experience with 13 patients. *J Urol.* 1985;134:1086-8. doi: 10.1016/s0022-5347(17)47635-x.
- Flores G, Nellen H, Magaña F, Calleja J. Acute bilateral emphysematous pyelonephritis successfully managed by medical therapy alone: A case report and review of the literature. *BMC Nephrol.* 2002;3:4. doi: 10.1186/1471-2369-3-4.
- Zabba A, Montie JE, Popowniak KL, Weinstein AJ. Bilateral

- emphysematous pyelonephritis. *Urology*. 1985;25:293-6. doi: 10.1016/0090-4295(85)90332-2.
4. Stein JP, Spitz A, Elmajian DA, Esrig D, Freeman JA, Grossfeld GD, et al. Bilateral emphysematous pyelonephritis: a case report and review of the literature. *Urology*. 1996;47:129-134. doi: 10.1016/s0090-4295(99)80399-9.
 5. Shokeir AA, El-Azab M, Mohsen T, El-Diasty T. Emphysematous pyelonephritis: a 15-year experience with 20 cases. *Urology*. 1997;49:343-6. doi: 10.1016/S0090-4295(96)00501-8.
 6. Tahir H, Thomas G, Sheerin N, Bettington H, Pattison JM, Goldsmith DJ. Successful medical treatment of acute bilateral emphysematous pyelonephritis. *Am J Kidney Dis*. 2000;36:1267-70. doi: 10.1053/ajkd.2000.19844.
 7. Kondo T, Okuda H, Suzuki M, Okumura T, Toma H. A case of emphysematous pyelonephritis improved with conservative therapy-indication for conservative therapy. *Hinyokika Kyo*. 2000;46:335-338.
 8. Shigemura K, Yasufuku T, Yamashita M, Arakawa S, Fujisawa M. Bilateral emphysematous pyelonephritis cured by antibiotics alone: A case and literature review. *Jpn J Infect Dis*. 2009;62:206-208.
 9. Mohsin N, Budruddin M, Lala S, Al-Taie S. Emphysematous pyelonephritis: A case report series of four patients with review of literature. *Ren Fail*. 2009;31:597-601. doi: 10.1080/08860220903003396.
 10. Mokabberi R, Ravakhah K. Emphysematous urinary tract infections: diagnosis, treatment and survival (case review series). *Am J Med Sci*. 2007;333:111-6. doi: 10.1097/00000441-200702000-00009.
 11. Ubee SS, McGlynn L, Fordham M. Emphysematous pyelonephritis. *BJU Int*. 2011;107:1474-8. doi: 10.1111/j.1464-410X.2010.09660.x.
 12. Yao J, Gutierrez OM, Reiser J. Emphysematous pyelonephritis. *Kidney Int*. 2007;71:462-5. doi: 10.1038/sj.ki.5002001.
 13. Huang JJ, Tseng CC. Emphysematous pyelonephritis: clinico-radiological classification, management, prognosis, and pathogenesis. *Arch Intern Med*. 2000;160:797-805. doi: 10.1001/archinte.160.6.797.
 14. Chen MT, Huang CN, Chou YH, Huang CH, Chiang CP, Liu GC, et al. Percutaneous drainage in the treatment of emphysematous pyelonephritis: 10-year experience. *J Urol*. 1997; 157:1569-73.
 15. Mydlo JH, Maybee GJ, Ali-Khan MM. Percutaneous drainage and/or nephrectomy in the treatment of emphysematous pyelonephritis. *Urol Int*. 2003;70:147-50. doi: 10.1159/000068776.
 16. Somani BK, Nabi G, Thorpe P, Hussey J, Cook J, N'Dow J. Is percutaneous drainage the new gold standard in the management of emphysematous pyelonephritis? Evidence from a systematic review. *J Urol*. 2008;179:1844-9. doi: 10.1016/j.juro.2008.01.019.
 17. Wan YL, Lee TY, Bullard MJ, Tsai CC. Acute gas-producing bacterial renal infection: correlation between imaging findings and clinical outcome. *Radiology*. 1996; 198:433-8. doi: 10.1148/radiology.198.2.8596845.
 18. Falagas ME, Alexiou VG, Giannopoulou KP, Siempos II. Risk factors for mortality in patients with emphysematous pyelonephritis: a meta-analysis. *J Urol*. 2007;178:880-5. doi: 10.1016/j.juro.2007.05.017.
 19. Kapoor R, Muruganandham K, Gulia AK, Singla M, Agrawal S, Mandhani A, et al. Predictive factors for mortality and need for nephrectomy in patients with emphysematous pyelonephritis. *BJU Int*. 2010;105:986-9. doi: 10.1111/j.1464-410X.2009.08930.x.

Copyright © 2020 The Author(s); Published by Society of Diabetic Nephropathy Prevention. This is an open-access article distributed under the terms of the Creative Commons Attribution License (<http://creativecommons.org/licenses/by/4.0>), which permits unrestricted use, distribution, and reproduction in any medium, provided the original work is properly cited.