

Journal of Nephropathology



A rare case of adenovirus infection in post renal transplant patient

Gittwa Vatsaraj Kottangal^{1*}, Seethalekshmy Vijayan Nalumakkal², Smitha Nalumakkal Vijayan²

¹Department of Pathology, Aster MIMS Hospitals, Kozhikode, Kerala, India

²Department of Pathology, Amrita Institute of Medical Sciences, Kochi 41, Kerala, India

ARTICLE INFO

Article type:
Case Report

Article history:
Received: 16 May 2021
Accepted: 27 Oct. 2021
Published online: 2 Jan. 2022

Keywords:
Adenovirus
Hemorrhagic cystitis
Immunocompromised
Necrotizing granuloma
Tubulointerstitial

ABSTRACT

Human adenovirus is a linear, non-enveloped, double-stranded DNA virus that can cause opportunistic infections. Typically, adenovirus infections result in self-limiting respiratory, gastrointestinal or ocular infections. However, it can cause severe disseminated disease in immunocompromised patients, especially in post-transplant recipients. In kidney transplant recipients, adenovirus infections have an incidence of up to 4.1%, usually manifested as hemorrhagic cystitis and tubulointerstitial nephritis, in the first three months post-transplant. Renal biopsy shows necrotizing granulomatous interstitial nephritis and other features consistent with the viral infection. Investigations like immunohistochemistry and polymerase chain reaction (PCR) help in confirmation of the diagnosis. Resolution of the disease with the reduction in immunotherapy alone supports the role of immunosuppression as a risk factor for adenovirus infection.

Implication for health policy/practice/research/medical education:

Adenovirus infection though commonly seen in the first three months of the post-transplant period, can occur late. Necrotizing granuloma is a distinctive histological feature of adenovirus infection. A panel of antiviral antibodies (AdV, SV40, CMV and HSV) and C4d are valuable in the differential diagnosis. If a granulomatous inflammation is present in a renal biopsy, adenovirus infection is a possibility in addition to the usual causes like tuberculosis, sarcoidosis, fungal infections, drugs and vasculitis.

Please cite this paper as: Kottangal GV, Nalumakkal SV, Nalumakkal Vijayan S. A rare case of adenovirus infection in post renal transplant patient. J Nephropathol. 2026;15(2):e17226. DOI: 10.34172/jnp.2022.17226.

Introduction

Adenovirus infection, one of the rare cause of renal allograft rejection usually have an onset in the early post-transplant period of 1-3 months. The virus can rarely infect up to eight months and very rarely after eight months (1). The adenoviral infection has been associated with *de novo* infection (particularly in pediatric recipients) and reactivation of the latent infection (2). Our patient presented with microhematuria in the tenth month of post-renal transplant, clinically an acute allograft rejection. Renal biopsy and the positive nuclear staining in immunohistochemistry clinched the diagnosis of adenoviral infection. The diagnosis of viral infection is important as a careful reduction of immunosuppression has a significant role in treatment.

Case Presentation

A 42-year-old man with hypertension and type 2 diabetes mellitus underwent unrelated live donor kidney transplantation for autosomal dominant polycystic kidney disease. Post-renal transplant days were uneventful and he was on triple-drug immunosuppression, namely, mycophenolate, tacrolimus and prednisolone. However, in the tenth month of post-transplantation, he developed macro haematuria and graft dysfunction. Investigations showed normal hemogram, blood urea; 34 mg/dL, serum creatinine: 2 mg/dL, urine PC (protein:creatinine) ratio; 5.41 and urine with numerous RBC, while urine culture was negative.

Renal biopsy showed a normal cortex. No glomerulitis/tubulitis/ vasculitis/peritubular capillaritis was noted in

*Corresponding author: Gittwa Vatsaraj Kottangal,
Emails: gittwa.vatsaraj@asterhospital.com, drgittwa@hotmail.com

the cortex. Medulla showed tubulitis with severe tubular destruction (Figure 1A). A few tubular epithelial cells had enlarged nuclei and smudgy chromatin consistent with viral cytopathy (Figure 1B). Dense inflammation in the interstitium with necrotizing granuloma and interstitial hemorrhage was noted (Figure 1C). The Immunofluorescence study for IgG, IgA, C3, C1q and kappa and lambda light chains was negative. Immunohistochemistry (IHC) for C4d, cytomegalovirus (CMV) and simian vacuolating virus 40 (SV40) were negative. Based on histology and immunohistochemistry, the diagnosis was given as necrotizing granulomatous interstitial nephritis, with interstitial hemorrhage involving medulla, suggestive of adenovirus infection. As IHC for adenovirus antigen was unavailable in our institution, the sample had to be outsourced for immunohistochemical evaluation. Urine BK virus was <100 cu/mL. S. CMV <57.1 cu/mL, urine TB (tuberculosis) PCR was negative. Being a country with a high incidence of tuberculosis, an immunocompromised patient with necrotizing granuloma, the patient was started on antitubercular therapy. Meanwhile, the immunohistochemical stain for adenovirus antigen showed nuclear staining in the tubular epithelial cells (Figure 1D), which confirmed adenoviral infection. Reduction in immunosuppression with five doses of intravenous immunoglobulin (IVIG) was given. The patient responded well to treatment and is doing well for the past four years with stable renal function.

Discussion

Adenoviruses are non-enveloped, lytic, double-stranded

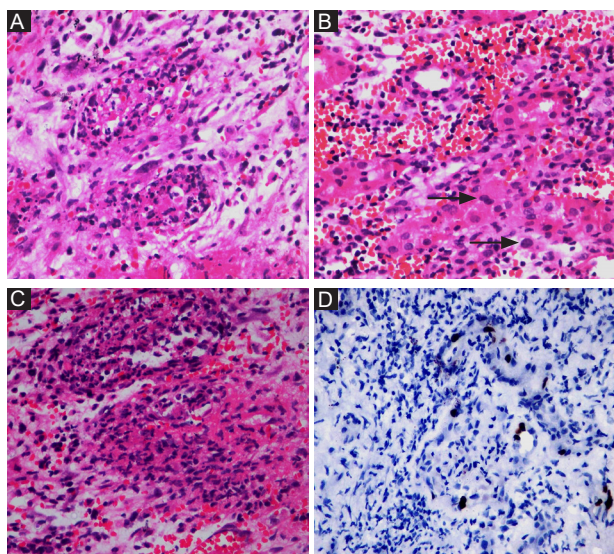


Figure 1. (A) Medulla with tubulitis and severe tubular destruction (H&E ×200). (B) Viral cytopathic effect in tubular epithelial cells with enlarged nuclei and smudgy chromatin (H&E). (C) Necrotizing granuloma and interstitial hemorrhage (H&E ×200). (D) Immunohistochemistry stain for adenovirus antigen (×400 objective).

DNA viruses (3), which in immunocompetent patients cause self-limited gastrointestinal, respiratory and conjunctival disease. Adenoviruses in solid organ transplant recipients cause intense, long-lasting, and even life-threatening infections, significantly impacting morbidity, mortality and graft survival (4). The disease is thought to be disseminated when two or more organs are involved (4). Adenoviruses attack the host immune response by impeding the interferon's effects and inhibiting apoptosis of the infected cell. They can also prevent primary human leukocyte antigen class I expression on the cell surface (3,4).

They are rarely seen in kidney transplant recipients (up to 4.1%) (5). Onset is typically in 1st three months post-transplant period. Adenovirus infection commonly occurs in early transplant days when the immunosuppression is intense. Late-onset disease, infected from 17 to 144 months, has been rarely reported (1,2,6). The infection is common in stem cell recipients (3-7%) and solid organ transplant recipients (5% to 22%). The native kidney is occasionally involved. Commonly seen in adults. Children less than five years are susceptible (7).

Kidney transplant recipients commonly present as gross hematuria. Fever (pyrexia of unknown origin), dysuria, acute graft rejection and graft tenderness are the other presentations. In renal transplant recipients, hemorrhagic cystitis is the most common clinical manifestation (5). Other manifestations include interstitial nephritis, acute tubular necrosis and ureteral obstruction with hydronephrosis. Rarely may present as a mass lesion in the kidney (4,7).

Diagnostic modalities include histopathology, immunohistochemistry, molecular study and enzyme immunoassay. The definite diagnosis is by real-time polymerase chain reaction (RT-PCR) and immunohistochemistry.

Renal biopsy microscopy shows severe tubular destruction with rupture of the basement membranes and foci of necrosis with leukocytosis. In addition, an interstitial mononuclear and plasma cell response sometimes with granuloma formation can be seen. Viral inclusion bodies in tubular epithelial cell nuclei (amorphous ground glass variants, sometimes smudgy basophilic central inclusion bodies surrounded by halos) may give a clue to the viral cytopathic effect (1,2,6). Distal tubules are infected more than proximal tubules and the tubular lumina shows detached infected cells and red cell cast. Focal interstitial hemorrhage and edema are seen. Vessels are usually unaffected. Viral cytopathic changes can rarely be seen in the parietal epithelial cells lining the Bowman's capsule (8).

Reduction of immunosuppressive drugs and antiviral drugs like cidofovir, ribavirin, valganciclovir or ganciclovir

is the first line of treatment. In addition, IVIG is also administered (5,9,10).

Better prognosis and recovery if localized and effectively treated. Disseminated diseases are often fatal (>60%) (1).

Histopathological differential diagnosis

Acute cellular rejection: Renal biopsy specimen may show reactive atypia of tubular nuclei, which mimic viral inclusions. Granulomas of other etiologies are at times seen associated with tubular destruction. Hemorrhage and tubular necrosis are less severe in rejection than adenovirus infection. Further evidence of rejection like endarteritis and C4d deposition (IHC) confirms the diagnosis of rejection (3).

The histologic features of various viral infections are summarized in Table 1.

Conclusion

The transplant pathologist is an essential part of health care providers managing renal transplant patients. Pathological examination of renal biopsy specimens forms an integral part of the diagnosis, management and prognosis of medical kidney diseases and post-transplant complications. Various pathological studies like light microscopy, histochemical special stains, immunofluorescence and immunohistochemistry help the pathologist to be a crucial decision-making body as described in this case. If a granulomatous inflammation is present in a renal biopsy, adenovirus infection is a possibility in addition to the usual causes like tuberculosis, sarcoidosis, fungal infections, drugs and vasculitis. Detection of viral infections in transplant biopsy is critical in cases of graft dysfunction as they are managed by reducing immunosuppression.

Acknowledgments

We would like to thank Dr. Mohammed Iqbal,

Consultant Nephrologist, Medical Trust Hospital, Kochi, Kerala, India – for clinical details; Department of Pathology, Amrita Institute of Medical Sciences, Kochi, Kerala; and Dr. Anila A Kurian, Center for Renal and Urological Pathology Private Limited, Chennai, Tamil Nadu, India - for IHC adenovirus.

Authors' contribution

Conceptualization: Gittwa Vatsaraj Kottangal.

Data curation: Gittwa Vatsaraj Kottangal, Seethalekshmy Vijayan Nalumakkal.

Formal analysis: Gittwa Vatsaraj Kottangal, Seethalekshmy Vijayan Nalumakkal.

Investigation: Seethalekshmy Vijayan Nalumakkal.

Methodology: All authors.

Project administration: Smitha Vijayan Nalumakkal.

Resources: Gittwa Vatsaraj Kottangal, Seethalekshmy Vijayan Nalumakkal

Software: Gittwa Vatsaraj Kottangal.

Supervision: Seethalekshmy Vijayan Nalumakkal.

Validation: Seethalekshmy Vijayan Nalumakkal, Smitha Vijayan Nalumakkal.

Visualization: Gittwa Vatsaraj Kottangal, Seethalekshmy Vijayan Nalumakkal.

Writing—original draft: Gittwa Vatsaraj Kottangal

Writing—review and editing: All authors.

Conflicts of interest

We declare that we have no competing interests.

Ethical issues

We have completely observed ethical issues (including plagiarism, data fabrication, double publication). This case report was conducted in accord with the World Medical Association Declaration of Helsinki. Patient has given us a written informed consent for publication as a case report.

Table 1. Histologic features of various viral infections

	Polyoma virus (BK)	Cytomegalo virus	Adeno virus	Epstein-Barr virus
Viral inclusion type				
Smudgy/ground glass nuclear	++	+	++	-
Central nuclear with halo	+	+++	+	-
Cytoplasmic	-	+	+/-	-
Sites of viral replication/staining				
Tubular epithelial cells	+++	+++	+++	-
Endothelial cells	-	++	-	-
Inflammatory cells	-	+/-	++	+++
Acute tubular injury/necrosis	+++/-	++++	++++	+/-
Focal parenchymal necrosis	-	+/-	++++	+++
Interstitial hemorrhage	-	-	++	+/-
Granulomatous inflammation	+/-	+/-	+++	-

Funding/Support

No funding support was received.

References

1. Hatlen T, Mroch H, Tuttle K, Ojogho O, Rooney M, Desmond S, et al. Disseminated Adenovirus Nephritis After Kidney Transplantation. *Kidney Int Rep.* 2017 Aug 12;3:19-23. doi: 10.1016/j.ekir.2017.08.004.
2. Watcharananan SP, Avery R, Ingsathit A, Malathum K, Chantratita W, Mavichak V, et al. Adenovirus disease after kidney transplantation: course of infection and outcome in relation to blood viral load and immune recovery. *Am J Transplant.* 2011;11:1308-14. doi: 10.1111/j.1600-6143.2011.03479.x.
3. Greber UF, Flatt JW. Adenovirus Entry: From Infection to Immunity. *Annu Rev Virol.* 2019;6:177-197. doi: 10.1146/annurev-virology-092818-015550.
4. Echavarría M. Adenoviruses in immunocompromised hosts. *Clin Microbiol Rev.* 2008;21:704-15. doi: 10.1128/CMR.00052-07.
5. Etta PK. Viral nephropathies in renal transplantation with a special emphasis on adenovirus infection. *Indian J Transplant* 2018;12:233-5. doi: 10.4103/ijot.ijot_38_18.
6. Singh HK, Nickleit V. Kidney diseases caused by viral infections. *Curr Diagn Pathol.* 2004;10:11-21.
7. Engen RM, Huang ML, Park GE, Smith JM, Limaye AP. Prospective assessment of adenovirus infection in pediatric kidney transplant recipients. *Transplantation.* 2018;102:1165-71. doi: 10.1097/TP.0000000000002100
8. Hatlen T, Mroch H, Tuttle K, Ojogho O, Rooney M, Desmond S, et al. Disseminated adenovirus nephritis after kidney transplantation. *Kidney Int Rep.* 2017;3:19-23. doi: 10.1016/j.ekir.2017.08.004.
9. Ison MG. Adenovirus infections in transplant recipients. *Clin Infect Dis.* 2006;43:331-9. doi: 10.1086/505498.
10. Rady K, Walters G, Brown M, Talaulikar G. Allograft adenovirus nephritis. *Clin Kidney J.* 2014;7:289-92. doi: 10.1093/ckj/sfu020.

Copyright © 2026 The Author(s); Published by Society of Diabetic Nephropathy Prevention. This is an open-access article distributed under the terms of the Creative Commons Attribution License (<https://creativecommons.org/licenses/by/4.0>), which permits unrestricted use, distribution, and reproduction in any medium, provided the original work is properly cited.