



## A case of severe nephrotic syndrome caused by isolated CMV glomerulopathy with ganciclovir resistant UL 97 mutation

Ramez R. Sunna<sup>1</sup>, Rupinder Sodhi<sup>1</sup>, Francis Arden Purvis<sup>2</sup>, Rosemary Ouseph<sup>1</sup>, David S. Brink<sup>3</sup>, Bahar Bastani<sup>1\*</sup>

<sup>1</sup>Department of Internal Medicine, Division of Nephrology, Saint Louis University School of Medicine, Saint Louis, Missouri, USA

<sup>2</sup>Transplant Institute, Saint Louis University School of Medicine, Saint Louis, Missouri, USA

<sup>3</sup>Department of Pathology, Saint Louis University School of Medicine, Saint Louis, Missouri, USA

### ARTICLE INFO

*Article type:*  
Case Report

*Article history:*  
Received: 17 June 2019  
Accepted: 29 July 2019  
Published online: 8 August 2019

*Keywords:*  
CMV glomerulopathy, CMV viremia,  
kidney transplant, UL 97 mutation,  
nephrotic syndrome, proteinuria,

### ABSTRACT

**Background:** While many cases of cytomegalovirus (CMV) nephropathy have been reported in the literature, isolated CMV glomerulopathy is considered a rare finding.

**Case Presentation:** We report the case of a CMV-negative recipient of kidney allograft from a CMV-positive donor (D+/R-), the recipient subsequently developed severe nephrotic syndrome secondary to biopsy-proven isolated CMV glomerulopathy.

**Conclusions:** The patient developed CMV viremia with ganciclovir resistant UL97 mutation. His treatment course was resistant to recommended dose of intravenous ganciclovir, so therapy was changed to foscarnet with resolution of his viremia and reduction in proteinuria.

### *Implication for health policy/practice/research/medical education:*

Clinicians need to be aware of CMV complications in the kidney transplant population.

*Please cite this paper as:* Sunna RR, Sodhi R, Purvis FA, Ouseph R, Brink DS, Bastani B. A case of severe nephrotic syndrome caused by isolated CMV glomerulopathy with ganciclovir resistant UL 97 mutation. J Nephrologist. 2019;8(4):e38. DOI: 10.15171/jnp.2019.38.

### 1. Background

Cytomegalovirus (CMV) infection is reported in 20% to 60% of all transplant recipients and is a significant cause of increased morbidity and mortality in this population (1). When compared with other organ transplant recipients, kidney transplant patients are at a lower risk for CMV infection, in part due to the lower burden of latent virus in the kidney allograft. Without prophylaxis, more than 50% of CMV D+/R- kidney allograft recipients develop symptomatic infection during the first three months after transplantation (2). In the absence of prophylaxis, CMV viremia is most likely to occur between the first and third months following transplant, when immunosuppression is at its maximum. However, the onset of CMV viremia has been delayed by the routine use of prophylactic antivirals in the early post-transplant period. Currently CMV infection typically occurs around 1-3 months after

the cessation of antiviral prophylaxis (3-5). The incidence of late-onset CMV disease after three months of CMV prophylaxis in high-risk kidney transplant recipients is reported to be 18%-31% (5). CMV may be transmitted to transplant recipients via infected donor organs or cellular blood products, or maybe due to reactivation of the latent virus in the organ recipient.

CMV infection is defined as the presence of detectable CMV replication in blood, i.e., CMV viremia, regardless of whether any signs or symptoms are present. On the other hand, CMV disease is defined as any evidence of CMV infection with attributable symptoms. CMV disease can be further categorized as CMV syndrome with fever, malaise, leukopenia, thrombocytopenia, or as a tissue-invasive disease (6). Available anti-CMV drugs include intravenous (iv) ganciclovir, oral valganciclovir, iv foscarnet, and iv cidofovir. These drugs interfere with

\*Corresponding author: Prof. Bahar Bastani,  
Email: bahar.bastani@health.slu.edu

viral replication by targeting CMV DNA polymerase. Selection of antiviral agent depends on the severity of clinical manifestations, the level of viremia, and the pattern of drug resistance.

Previous studies have shown clinical benefit of prolonged valganciclovir prophylaxis given for 200 days after transplantation in D+/R- kidney transplant patients (3). In the study reported by Humar et al, 326 patients were allocated to a group that received valganciclovir for 200 days vs. 100 days in the other group. The group who received the antiviral prophylaxis for 200 days had lower incidence of CMV disease by 12 months post-transplant (16% vs. 36%), less CMV viremia (37% vs. 51%), and fewer cases of biopsy-proven acute rejections (11% vs. 17%) than the group who received prophylaxis for only 100 days (3). Others have also shown that late-onset CMV disease affects 21%-37% of D+/R- kidney transplant patients within two years after transplantation (1,4,7). While the FDA-recommended dose of valganciclovir for CMV prophylaxis is 900 mg daily, a dose of 450 mg daily is used by a number of centers (8). A meta-analysis by Kalil et al, showed that prophylaxis with valganciclovir 900 mg vs. 450 mg daily yielded similar clinical efficacy (9).

In patients with active CMV infection or disease, it is recommended to monitor virologic response to treatment with weekly quantitative polymerase chain reaction (PCR) in order to follow the course of response to treatment and to identify patients who are or become refractory to treatment due to emergence of resistant strains. Differential diagnosis of CMV nephropathy includes polyoma virus nephropathy, adenovirus tubulointerstitial nephritis, acute cellular rejection, antibody-mediated rejection and acute glomerulonephritis.

CMV is a well-known cause of plasma cell-rich tubulointerstitial nephritis with cytopathic changes in tubular epithelial cells. However, involvement of glomeruli and larger arteries in the absence of tubulointerstitial disease is rare. Herein we present a case of a CMV-negative kidney transplant recipient from a CMV-positive deceased donor. The recipient subsequently developed progressive massive proteinuria and biopsy-proven isolated CMV glomerulopathy without any tubulo-interstitial involvement by the CMV infection.

## 2. Case Report

A 63-year-old African-American man with a medical history of end stage kidney disease (ESRD) secondary to prolonged hypertension received a deceased donor kidney transplant in October of 2017. The donor and recipient were HLA 2A/1B/2DR mismatch, CMV D+/R-transplantation. He underwent induction therapy with thymoglobulin, a total dose of 6mg/kg, and intravenous

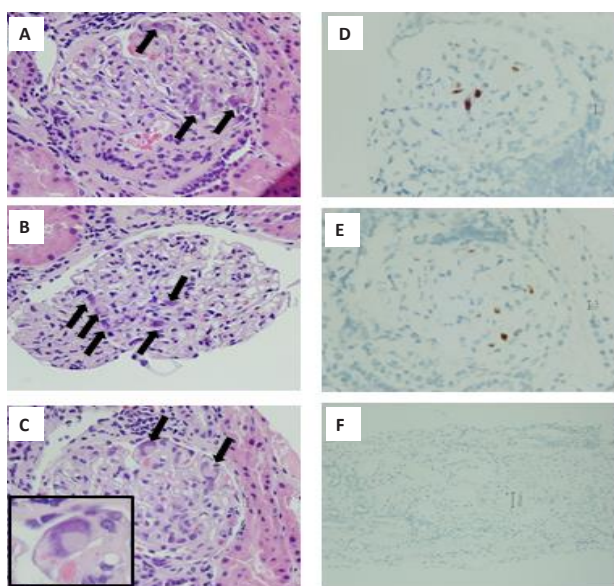
methylprednisolone. Maintenance immunosuppression regimen per our transplant center protocol included mycophenolic acid (Myfortic) 360 mg twice a day, iv steroids tapered down to oral prednisone 5 mg daily by post-operative day five, tacrolimus (Prograf) targeting a 12-hour trough level of 8-10 ng/mL for the first three months, followed by a trough level of 7-9 ng/ml in the following three months, and finally a trough level of 4-7 ng/mL after six months. Additionally, he received CMV prophylaxis with oral valganciclovir 450 mg daily and trimethoprim/sulfamethoxazole (160 mg/800 mg nightly) for 6 months after transplantation as per our center protocol.

His post-transplant course was complicated by new-onset diabetes after transplant and early CMV viremia that was first detected while on prophylactic valganciclovir around January 2018. At that time, his mycophenolic acid was discontinued and he was started on therapy with oral valganciclovir, 900 mg twice a day. His CMV PCR titers resolved, so therapy was reduced to 900 mg daily. His CMV viremia reactivated again in March 2018 and at that time, the dose of valganciclovir was increased to 900 mg twice a day. At that point, he did not have any significant proteinuria and his kidney function was preserved with a baseline serum creatinine level of 1.2-1.4 mg/dL.

His random urine protein: creatinine ratio gradually increased, reaching 1g/g of creatinine in May 2018, then 2 g/g by the end of the following month. Since he was not showing virologic response to treatment, he received one dose of iv immunoglobulin (IVIg) 1 g/kg of body weight.

Due to worsening of proteinuria and increasing CMV viremia, he underwent allograft biopsy at the end of June 2018. Microscopic examination of the biopsy sample showed 19 glomeruli, none of which was sclerotic. Glomeruli showed focal mesangial expansion and mesangial hypercellularity. Several glomeruli showed viral cytopathic effect consistent with CMV infection (Figures 1A, 1B and 1C). The interstitium showed minimal expansion by fibrosis and contained a multifocal inflammatory infiltrate composed predominantly of lymphocytes and plasma cells. There was minimal tubular atrophy. Nonatrophic tubules showed no significant tubulitis. Arteries were unremarkable. Peritubular capillaries showed no significant increase in intraluminal leukocytes. Immunohistochemical staining for CMV showed occasional glomerular cells with positive label (Figures 1D and 1E) and was negative in tubules and in the interstitium (Figure 1F). Immunohistochemical staining for polyomavirus was negative.

Due to persistent and worsening CMV viremia, resistance testing was done that showed a gancyclovir-resistant CMV UL97 mutation. Because that subtype of mutation was theoretically susceptible to high-dose



**Figure 1.** A-C: Three glomeruli, each with several cytomegalic cells (arrows) with intranuclear and intracytoplasmic inclusions characteristic of cytomegaloviral cytopathic effect. The affected cells may represent endothelial cells and/or podocytes. (Hematoxylin & eosin stain). D-E: Immunohistochemical staining of two glomeruli for CMV shows positive label (brown) in several cells in each glomerulus. (CMV immunoperoxidase). F: Immunohistochemical staining shows negative label in tubules and interstitium. (CMV immunoperoxidase).

ganciclovir treatment, a course of iv ganciclovir was instituted, however CMV PCR titers continued to rise, peaking at 89 000 IU/mL in August of 2018, and proteinuria peaked at 29 g/day by September of 2018. A repeated resistance study showed a second CMV UL54 mutation that was completely ganciclovir- and cidofovir-resistant. His kidney function was preserved throughout

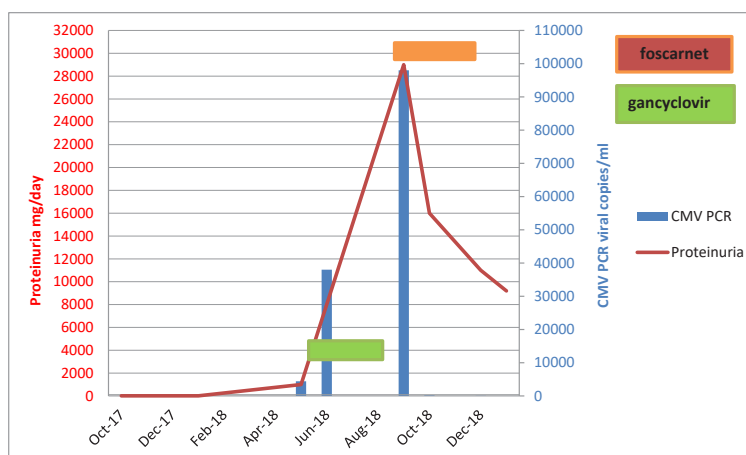
the course of CMV viremia and proteinuria.

Therapy was then changed to iv foscarnet. Quantitative CMV PCRs showed good response to the treatment, reaching less than 50 IU/mL by the end of October of 2018, and his proteinuria has declined to a level of 11 g/day by the end of November of 2018. An overview of the patient's clinical course is shown in Figure 2.

### 3. Discussion

CMV infection continues to have a tremendous impact in the field of solid organ transplantation despite medical advances in its diagnosis, prevention, and treatment. CMV remains one of the most common complications affecting organ transplant recipients with significant morbidity and occasional mortality.

While CMV nephropathy has been mentioned in many reports, isolated CMV glomerulopathy in allografts remains a rare entity. In our review of the literature, Richardson et al, was the first to suggest CMV associated glomerulopathy in kidney allografts in 1981 (10). In that report, the authors investigated the relation between CMV infection and kidney allograft dysfunction in 14 patients. In 7 patients, allograft dysfunction occurred during clinically manifest CMV infection. In 5 of these patients biopsies revealed little or no tubulointerstitial change, but a distinctive diffuse glomerulopathy characterized by enlargement or necrosis of endothelial cells and accumulation of mononuclear cells and fibrillar material in glomerular capillaries. Biopsies in the remaining patients revealed predominantly tubulointerstitial changes typical of cellular rejection, and most of these patients did not have viremia. One additional patient, studied prospectively, manifested both forms of allograft injury; tubulointerstitial changes



**Figure 2.** The trend of CMV PCR against the level of proteinuria and the therapeutic effect of iv ganciclovir compared to iv foscarnet on both PCR and proteinuria. Foscarnet was given during the months of September to November 2018. The area in green shows the duration over which ganciclovir was administered. The area in orange shows the duration over which foscarnet was administered.

occurring two weeks after transplantation [and responding to escalating immunosuppression], and CMV-associated glomerulopathy occurring 7 weeks after transplantation [and responding to decreased immunosuppression] (10).

Subsequently, several additional reports discussed the relationship between CMV viremia and glomerular injury following transplantation. The case report by Payton et al, in 1987, showed CMV inclusions in glomerular and peritubular capillary endothelial cells and tubular epithelial cells on light microscopy, but no CMV inclusions were seen on electron microscopy (11). Another case report by Birk and Chavers demonstrated glomerular capillary intracytoplasmic CMV inclusions in the kidney allograft biopsy (12). However, the existence of CMV-associated glomerulopathy has been questioned by Herrera et al, who suggested that the glomerular changes described by Richardson et al, as CMV glomerulopathy could be a form of acute transplant rejection (13).

The present case demonstrates that isolated CMV glomerulopathy, without any significant tubulointerstitial involvement can be caused by direct CMV infection of glomerular capillary endothelial cells and podocytes. The involvement of the latter is possibly responsible for massive degrees of proteinuria seen in our patient.

CMV disease remains a challenge to treat. CMV infection in kidney transplant patients demands aggressive management to avoid CMV-induced complications in the immunosuppressed patient. While ganciclovir is an effective treatment for CMV infection, emergence of mutation-driven viral drug-resistance, as seen in our case, can limit its therapeutic usefulness. Ganciclovir-resistant CMV is an important cause of late morbidity among CMV D+/R- transplants who have had long exposure to ganciclovir and have received highly potent immunosuppression. In a retrospective study by Limaye et al, ganciclovir-resistant CMV disease developed in 7% of CMV-seronegative recipients of CMV-seropositive organs. Among those patients who developed CMV disease within one year after transplantation, 20% of the cases developed ganciclovir-resistant CMV disease (14).

#### 4. Conclusions

Screening for CMV viremia and measuring CMV viral load by PCR in the post-transplant period remains an important aspect of practice, in order to diagnose infection early in the course so as to prevent serious complications. As we show in the present case, CMV glomerulopathy can present with worsening proteinuria without other clinical or laboratory manifestations. Treatment with oral valganciclovir, iv ganciclovir, foscarnet and cidofovir remain available and should be chosen based on severity of viremia and signs/symptoms, organ involvement and drug

resistance/sensitivity status.

#### Acknowledgements

The authors would like to thank all of the transplant nephrology team at Saint Louis University hospital for their hard work and follow up care of this complex patient.

#### Authors' contribution

All authors contributed in data collection and preparation of the report.

#### Conflicts of interest

The authors declare no conflict of interest

#### Ethical consideration

Since there were no patient identifiers, a consent form was not required.

#### Funding/Support

There was no source of funding for this publication.

#### References

1. Weikert BC, Blumberg EA. Viral Infection after Kidney Transplantation: Surveillance and Management. *Clin J Am Soc Nephrol.* 2008;3(2):76–86. doi: 10.2215/CJN.02900707.
2. Sagedal S, Nordal KP, Hartmann A, Degré M, Holter E, Foss A, et al. A prospective study of the natural course of cytomegalovirus infection and disease in kidney allograft recipients. *Transplantation.* 2000;70(8):1166–74. DOI: 10.1097/00007890-200010270-00007.
3. Humar A, Lebranchu Y, Vincenti F, Blumberg EA, Punch JD, Limaye AP, et al. The efficacy and safety of 200 days valganciclovir cytomegalovirus prophylaxis in high-risk kidney transplant recipients. *Am J Transplant.* 2010; 10(5): 1228–37. doi: 10.1111/j.1600-6143.2010.03074.x.
4. Helanterä I, Kyllönen L, Lautenschlager I, Salmela K, Koskinen P. Primary CMV infections are common in kidney transplant recipients after 6 months valganciclovir prophylaxis. *Am J Transplant.* 2010;10(9):2026–32. doi: 10.1111/j.1600-6143.2010.03225.x.
5. Helanterä I, Lautenschlager I, Koskinen P. Prospective follow-up of primary CMV infections after 6 months of valganciclovir prophylaxis in kidney transplant recipients. *Nephrology Dialysis Transplantation.* 2009;24(1):316–20.
6. Kotton CN, Kumar D, Caliendo AM, Asberg A, Chou S, Snydman DR, et al. International consensus guidelines on the management of cytomegalovirus in solid organ transplantation. *Transplantation.* 2010;89(7):779–95. doi: 10.1097/TP.0b013e3181cee42f.
7. Humar A, Limaye AP, Blumberg EA, Hauser IA, Vincenti F, Jardine AG, et al. Extended valganciclovir prophylaxis in D+/R- kidney transplant recipients is associated with long-term reduction in cytomegalovirus disease: Two-year results of the IMPACT study. *Transplantation.* 2010;90(12):1427–31.

8. Luan FL, Kommareddi M, Ojo AO. Impact of Cytomegalovirus Disease in D+/R- kidney transplant patients receiving 6 months low-dose valganciclovir prophylaxis. *Am J Transplant*. 2011;11(9):1936-42. doi: 10.1111/j.1600-6143.2011.03611.x.
9. Kalil AC, Mindru C, Florescu DF. Effectiveness of Valganciclovir 900 mg versus 450 mg for cytomegalovirus prophylaxis in transplantation: Direct and indirect treatment comparison meta-analysis. *Clin Infect Dis*. 2011;52(3): 313–21. doi: 10.1093/cid/ciq143.
10. Richardson WP, Colvin RB, Cheeseman SH, Tolkoff-Rubin NE, Herrin JT, Cosimi AB, et al. Glomerulopathy associated with cytomegalovirus viremia in kidney allografts. *N Engl J Med*. 1981;305(2):57-63. doi: 10.1056/NEJM198107093050201.
11. Payton D1, Thorner P, Eddy A, Yeager H, Baumal R. Demonstration by light microscopy of cytomegalovirus on a kidney biopsy of a kidney allograft recipient: confirmation by immunohistochemistry and in situ hybridization. *Nephron*. 1987;47(3):205-8. doi: 10.1159/000184493.
12. Birk PE, Chavers BM. Does cytomegalovirus cause glomerular injury in kidney allograft recipients? *J Am Soc Nephrol*. 1997;8(11):1801-08.
13. Herrera GA, Alexander RW, Cooley CF, Luke RG, Kelly DR, Curtis JJ, et al. Cytomegalovirus glomerulopathy: A controversial lesion. *Kidney Int*. 1986;29(3):725-33.
14. Limaye AP, Corey L, Koelle DM, Davis CL, Boeckh M. Emergence of ganciclovir-resistant cytomegalovirus disease among recipients of solid-organ transplants. *Lancet*. 2000;356(9230):645-49. doi: 10.1016/S0140-6736(00)02607-6.

**Copyright** © 2019 The Author(s); Published by Society of Diabetic Nephropathy Prevention. This is an open-access article distributed under the terms of the Creative Commons Attribution License (<http://creativecommons.org/licenses/by/4.0>), which permits unrestricted use, distribution, and reproduction in any medium, provided the original work is properly cited.